

REIMBURSEMENT - ABI-Q SYSTEM WITH EXERCISE

Background: Around 30% of patients experiencing symptoms of PAD, despite a normal diagnosis at rest, exhibit abnormal results following exercise. The diagnostic accuracy of ABI testing for PAD can be significantly improved by incorporating exercise into the evaluation process.

The ABI-Q exam is reimbursable using CPT Code 93923 | National Average \$139 (2024)

The ABI-Q examination utilizes pulse volume recording (PVR) technology to assess lower extremity arterial blood flow and aid in the diagnosis of peripheral artery disease (PAD). The ABI-Q examination can be performed as a standalone assessment using the ABI-Q system, or as part of a comprehensive vascular evaluation with the SimpleABI Cuff-Link Systems.

The following information outlines the ABI-Q with exercise procedure on a simpleABI-Q standalone system:

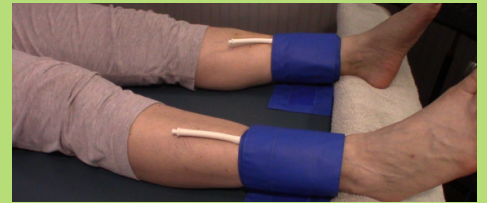
The ABI-Q exam is a single level study. If the patient is exercised as part of the exam, it will satisfy the CPT code 93923. (Exercise is an example of a "provocative functional maneuver" that brings on symptoms of the disease)



1

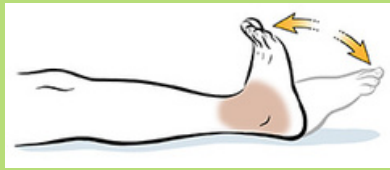
Wrap a Cuff

Have patient lie down in the supine position on the exam table. Securely wrap 10cm cuffs one inch above their ankle. Attach the hose from the PVR control unit to right cuff.



2

Perform exercise

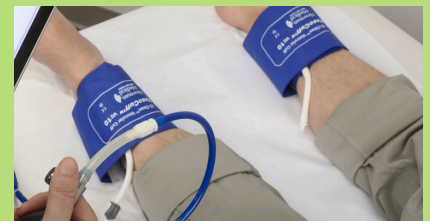

Have the patient exercise to increase blood flow to the lower extremities. **PREFERRED METHOD:** While laying on the table, patient should perform 50 dorsiflexions (raising the toes towards the shin).

3

Push a button

Obtain PVR waveform: Inflate cuff to 80 mmHg, then slowly deflate to 65 mmHg. When the pressure gauge turns green, click Get Waveform. Keep patient still and quiet. The waveform will start to appear within 10 seconds. Release the air in the cuff and move the hose to the left leg cuff and repeat the above steps.



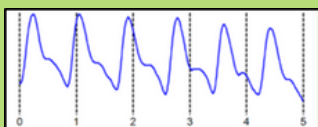
4

Get Results - Save Report

ABI-Q Guidelines

NORMAL

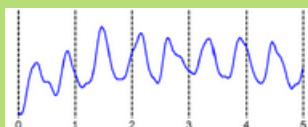
> 1.00



Normal PVR waveforms have a sharp upstroke and a prominent reflected wave in late systole or diastole.

BORDERLINE

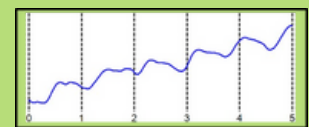
0.91 - 0.99



Borderline abnormal PVR waveforms will cause the waveform to broaden and the reflected wave (diastolic notch) will not be present.

ABNORMAL

< 0.90



Severely abnormal PVR waveforms have little to no amplitude, or even appear as a 'flatline'.